

Panoramic Images versus Three-Dimensional Planning Software for Oral Implant Planning in Atrophied Posterior Maxillary: A Clinical Radiological Study

Thomas Fortin;^{*†} Elsa Camby;^{‡§} Mahdi Alik;^{‡§} Michel Isidori;^{‡§} Hervé Bouchet, DDS^{‡§}

ABSTRACT

Purpose: The objectives of this radiographic study were to determine to what degree the available residual bone area for implant placement was underestimated on panoramic radiographs (by comparison with multislice computed tomography CT/cone beam CT images combined with planning software) and to what degree the rate of severely resorbed posterior maxillae requiring sinus lift was overestimated on panoramic radiographs (by comparison with planning software in combination with strategic implant placement).

Materials and Methods: During a 2-year period, every patient who presented for the placement of implants in the posterior maxilla was examined by three practitioners to discuss the treatment plan. When two to three practitioners indicated a sinus lift with creation of a lateral window, a CT scan was performed and examined using dedicated three-dimensional software by a clinician familiar with the Computer Assisted Design/ Computer Assisted Manufacturing (CAD/CAM) implant placement protocol. For each tooth to be replaced, the presence of anatomical features such as anterior or posterior wall, palatal curvature, and septa were examined in view of the placement of an 8-mm or longer implant.

Results: One hundred one patients were studied in this case series for the treatment of 135 edentulous spans accounting for 301 missing teeth. After examination of the CT data on the three-dimensional software, 202 teeth (67.1%) could be replaced using a CAD/CAM procedure; 60.7% of the edentulous spans could be completely repaired by a crown or bridge supported by implants. In addition, 67.3% of edentulism with no teeth posterior to the span could be completely repaired using a fixed prosthesis supported by implants.

Conclusion: This radiological study demonstrates that the use of a panoramic exam for oral implant planning in severely resorbed maxillae overestimates the need for a sinus augmentation procedure when compared with the use of both three-dimensional planning software and strategic implant placement on small remaining bone volume.

KEY WORDS: CT imaging, panoramic images, planning, radiological assessment, sinus floor elevation

*Associate professor, Departement of Oral Surgery, Dental University of Lyon, Lyon, France; †professor, Laboratory of Traitement de l'Image et Modélisation Cognitive, UJF-Grenoble 1 / CNRS / TIMC-IMAG UMR 5525, Grenoble, F-38041, France; ‡clinical associate professor, Implant Dentistry, Hospices Civils de Lyon, Lyon, France; §private practice, France

Reprint requests: Prof. Thomas Fortin, 18 rue Joseph Cugnot, 38300 Bourgoin Jallieu, France; e-mail: thomas.fortin@univ-lyon1.fr

© 2011 Wiley Periodicals, Inc.

DOI 10.1111/j.1708-8208.2011.00342.x

INTRODUCTION

In severely resorbed posterior maxilla, implant placement posterior to the first premolar requires bone grafting, a well-documented procedure in the literature^{1,2} with favorable outcome for the intervention as well as for future implants.³⁻⁵ The drawbacks of sinus lift are its invasiveness, the increase in treatment duration and cost, the choice of a donor site, possible surgical complications both on the donor and host sites, and patient acceptance. To avoid a grafting procedure, placing implants on residual bone volume has been suggested by combining four concepts: implant tilting,⁶⁻¹² short implants,^{13,14} reduced number of implants,

and decreased number of dental units. The implant placement procedure should be either conventional^{6,11} or image guided.¹² Thus, prior to implant placement, the radiological exam should highlight the remaining bone volume. Panoramic radiography is the most commonly used examination for oral implant placement in the upper jaw according to the European Association for Osseointegration guidelines.¹⁵ The panoramic X-ray can provide a sufficient view of the residual crest height under the sinus floor. For anatomical features such as the anterior or posterior wall and the septa of the sinus, the palatal curvature, and the pterygoid process, one must consider that panoramic image quality is highly dependent on the radiologist's skill and remains a two-dimensional image of a three-dimensional volume with superimposition of anatomical structures that may make the assessment of the true anatomical situation surrounding the sinus cavity uncertain.

The objectives of this radiographic study were to estimate to what degree the available residual bone area for implant placement was underestimated on panoramic radiographs (by comparison with multislice computed tomography [CT]/cone beam CT images combined with planning software) and to what degree the rate of severely resorbed posterior maxillae requiring sinus lift using panoramic radiographs was overestimated (by comparison with planning software in combination with the four aforementioned clinical concepts).

MATERIALS AND METHODS

During a 2-year period, consecutive patients who presented at the department of oral surgery (University Hospital, Lyon, France) for the placement of implants in the posterior maxilla were eligible for inclusion in this radiographic study.

Primary planning was based on intraoral findings and standard radiological exams, either an intraoral or a panoramic radiograph (Cranex Tome®, Soredex, Tuusula, Finland). When the treatment option decided by the dental surgeon was sinus elevation with creation of a window in the lateral antral wall, standard radiological exams were submitted to three practitioners who are well trained in implant dentistry. These three practitioners expressed opinions while blinded to each others' observations. Based on this examination, each practitioner had to decide whether the treatment option for each edentulous span would be:

- Sinus lift by compacting bone using an osteotome instrument to gain bone volume;
- Sinus elevation with creation of a window in the lateral antral wall; and
- Placement of short implants.

When two to three practitioners indicated a sinus lift with creation of a lateral window, the patient was included in the study (Figure 1A). A conventional radiographic guide made of transparent acrylic resin and radiopaque teeth was made. Axial images via multislice CT (Somatom Plus S®, Siemens, Erlangen, Germany) or three-dimensional images via cone beam CT (NewTom VGI, Verona, Italy) were then made with the radiographic guide in the mouth. The time between the two radiographic examinations varied from 1 to 3 months. CT images were then examined using the three-dimensional Easy-Guide® planning software (Keystone-Dental, Burlington, MA, USA), by a clinician familiar with image-guided surgical procedure for the treatment of resorbed posterior maxilla.¹² For each tooth to be replaced, the presence of residual bone was examined. Implant placement was judged acceptable if an 8-mm or longer implant could be placed in an upright or tilted position using a conventional drill set sequence or the assistance of a guidance template depending on the prosthetic tooth (Figures 1B and 2).

RESULTS

One hundred twenty-eight patients were examined during the study period. After the standard exams were assessed by the three practitioners, 101 patients were included in this case series for the treatment of 135 edentulous spans (Table 1), accounting for 301 missing teeth to be replaced by 8-mm or longer osseointegrated implants (55% males, 45% female; mean age 59 years; range 41–82 years). After examination of the CT data using the computerized planning software, 202 teeth (67.1%) could be replaced (Table 1). The first premolar could be replaced in 89.3% of cases, the second premolar in 71.4%, the first molar in 51.8%, and the second molar in 75.5%. Considering the 135 edentulous spans (Table 2), 82 (60.7%) could be completely repaired by crown or bridge supported by implants. A single missing tooth could be replaced in only 54.1% of cases, while three and four missing teeth could be replaced in 71.4% and 72.2%, respectively. If the 92 cases of edentulism with no teeth posterior to the span are considered, 62

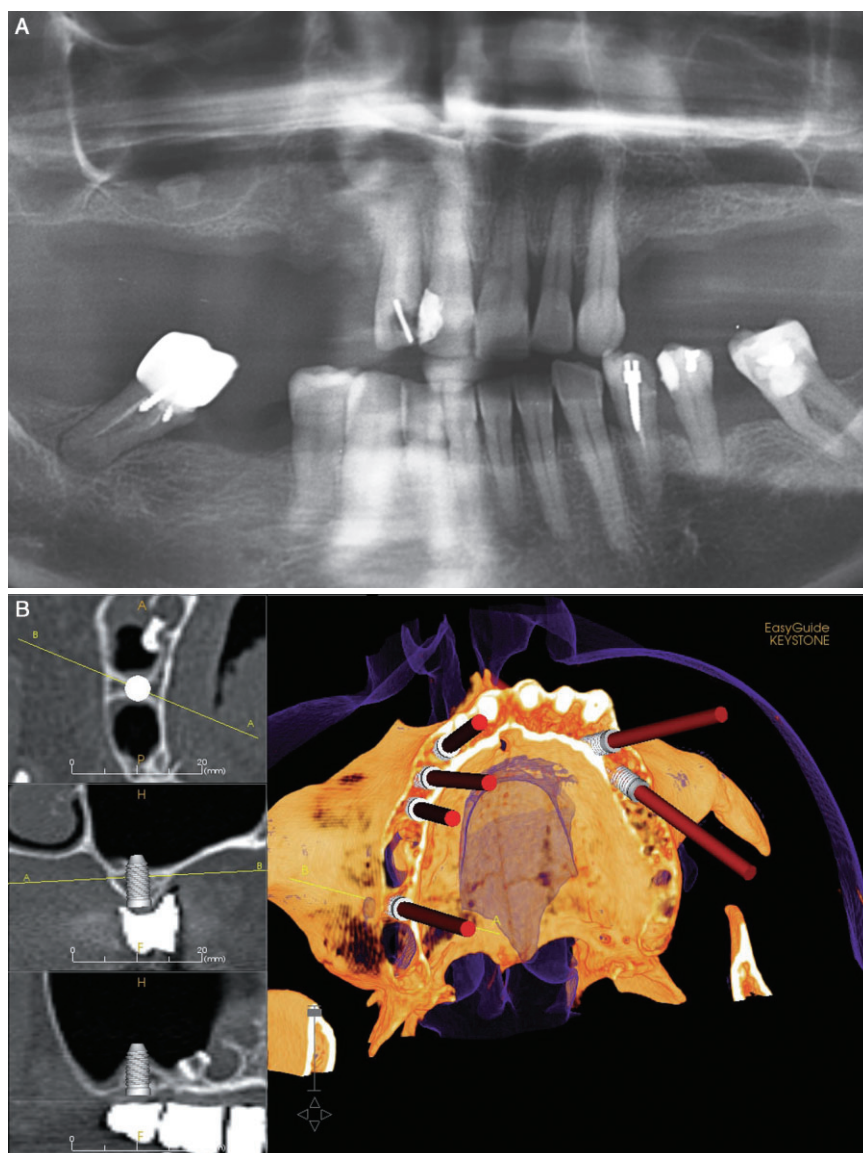


Figure 1 (A) Panoramic radiography highlighting a very limited amount of bone in the posterior maxilla. Patients were considered for this study when at least two practitioners indicated a sinus lift with creation of a lateral window. (B) Three-dimensional images for the placement of an implant on the septa in front of the second molar to avoid a sinus lift.

(67.3%) could be completely repaired by a fixed prosthesis supported by implants. The length and diameter of planned implants ranged from 8 to 12 and 4 to 5 mm, respectively. Angulations, depending on the location, ranged from 1 to 46° (Table 3).

DISCUSSION

In this radiological study, the combination of cross-sectional exams associated with dedicated planning software instead of a panoramic exam and four clinical concepts (implant tilting, short implants, reduced number of implants, and decreased number of dental

units) was used to optimize placement planning for oral implants in atrophied posterior maxillary. Conventional placement and an image-guided procedure to handle small bone volume were considered. To our knowledge, this is the first report that attempts to quantify the overestimation of the sinus augmentation procedure caused by the use of the panoramic exam. Panoramic radiographs systematically underestimate the available remaining bone for implant placement in the severely atrophic posterior maxillae. The inferiority of panoramic radiographs, when compared with cross-sectional images, has already been highlighted for

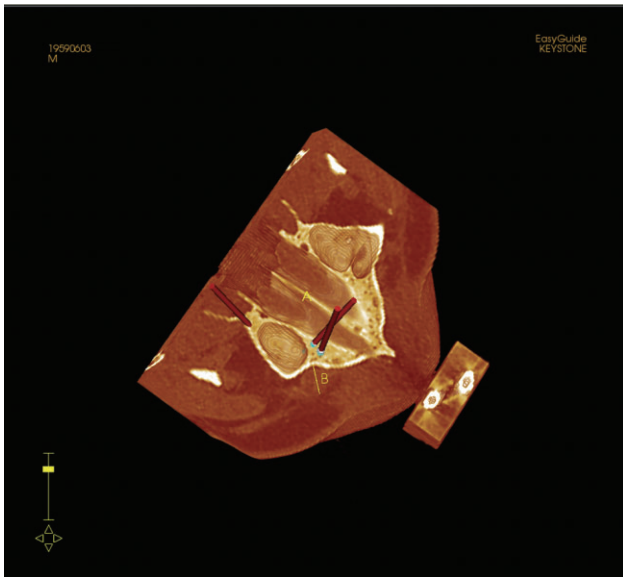


Figure 2 Implants are planned around the cavity (anterior wall and palatal curvature, posterior wall), not only on a plane passing through the cavity.

implant planning. In fact, cross-sectional images associated with dedicated planning software provide accurate measurements and predictable planning for both the number and location of implants to be planned.^{16–18} Several aspects have a negative impact on the reliability of panoramic radiographs. Malpositioning the patient leads to discrepancies and distortion.¹⁹ The panoramic

X-ray is a two-dimensional image of a three-dimensional volume, with superimposition of neighboring anatomical structures, real or ghost structures, and shadows of soft tissue and air. Oblique projection geometry also hampers good visualization. Panoramic radiographs have an inherent horizontal magnification, particularly in the upper premolar region, that makes planning more haphazard and less reliable because of a variable degree of overlap.

The clinical approach used in this study demonstrates that bone grafting for implant placement in the antrum region considered to be severely atrophied according to the standard radiological exam is not always necessary. Indeed, we found the prerequisite anatomical features in 67.3% of the teeth to be replaced. The vast majority of first premolars and second molars can easily be replaced without grafting, while half of the first molars required a graft. When considering edentulous spans, 60.7% could be completely repaired with a fixed prosthesis – a crown or bridges – supported by implants, increasing to 67.3% when patients had no teeth posterior to the edentulous section, given that the posterior teeth can take advantage of the posterior wall of the sinus to support a bridge. This could also be used for the completely edentulous patient because posterior cantilevers are considered an option to replace molars.²⁰ In some

TABLE 1 Missing Teeth and Occurrence			
Type of Missing Teeth and Occurrence	Occurrence	of Missing Teeth Replaced without Graft	% of Missing Teeth Replaced without Graft
First premolar	28	25	89.3
Second premolar	63	45	71.4
First molar	112	58	51.8
Second molar	98	74	75.5
Total	301	202	67.1

TABLE 2 Number of Missing Teeth, Edentulous Span, and Occurrence					
Edentulism	Single Tooth	2 Missing Teeth	3 Missing Teeth	4+ Missing Teeth	Total
With distal tooth	20	18	5		43
Free posterior	4	40	30	18	92
Completely restored (number)	13	31	25	13	82
Completely restored (%)	54.1	53.4	71.4	72.2	60.7

TABLE 3 Distribution of Implants according to Location, Inclination, and Length

Location	Inclination (Range, Degree)	Implant Length (Range, mm)	Implant Diameter (Range, mm)
Anterior wall	1 to 36	8 to 12	4 to 4.3
Septa	7 to 26	8 to 10	4 to 5
Palatal curvature	9 to 32	10 to 12	4 to 5
Posterior wall	17 to 24	10	4 to 5
Buccal curvature	29 to 46	10	4 to 5
Combination of anterior wall and palatal curvature	16 to 31	10	4 to 4.3

situations, not replacing the second molar can also be considered an option.²¹

Three-dimensional analysis outperforms the planning procedure because the surgical strategies are different when they are planned with standard radiographic exams or when they are planned with dedicated three-dimensional software. Implants are planned throughout the sinus cavity, not only on a plane passing through the cavity (Figure 2). Indeed, with intraoral radiography or a panoramic view, the modalities used in this clinical study, the practitioner cannot evaluate the complexity of the bone volume, because the data are presented in a two-dimensional format that superimposes the different structures.¹⁶ Neither small bone volume nor their particular orientation can be properly assessed by the practitioner. To analyze large cavities such as the maxillary sinuses, CT is more appropriate. Jacobs and colleagues¹⁷ have demonstrated that the use of dedicated three-dimensional software outperforms the analysis. With dedicated three-dimensional software, the orientation of reformatted slices is chosen by the practitioner to match the clinical need. On the contrary, either axial or reformatted slices provided by the radiologist are displayed in a pre-calculated orientation, perpendicular to the native axial slices. Ideally, reformatted slices should pass through the implant axis that matches prosthetic request and the available bone. Thus, it should highlight a small amount of bone if such is the case. Because different levels of atrophy are frequently present in the same area of the posterior maxilla, we often choose the lowest value in terms of width and height to classify the defect and treat it. Contrary to CAD/CAM guidance, the highest value of remaining bone in this bone volume has to be taken into consideration for the treatment strategy. This reduces the need for additional surgery such as grafting.

The use of the aforementioned anatomical features, except the septa, has already been described.^{6,11} This paper presents the addition of software that can accurately analyze the three-dimensional bone volume and image-guided procedure that provides accurate guidance during the implant placement process to take advantage of a possibly limited amount of bone. An image-guided procedure reduces the invasiveness of the surgical procedure. It is not necessary to raise a flap or to insert a straight probe on the sinus to visualize the sinus wall.⁶ Furthermore, it allows the surgeon to take advantage of the septa and palatal curvature, an option that is not routinely described in conventional procedures. The septa are sometimes intact: 31.7% of sinus floors with at least one septum were observed by Ulm and colleagues²². Most septa are located in the region between the second and the first premolar, with a mean height of 7 mm. With the image-guided procedure, the septa are no longer considered a possible complication but rather an advantage.

The radiological data obtained within this study must now be confirmed in long follow-up clinical studies. In fact, implant placement in limited residual bone volume also requires reducing the length and number of implants, and angulating them. There is evidence that these clinical concepts are effective solutions. Placement of short implants has been described as a valuable alternative to sinus grafting.^{13,14,23,24} In this study, short implants were planned for the anterior wall and the septa.

With the procedure proposed in this paper, implants are often tilted, which does not seem to be a drawback because preliminary studies on tilted implants have indicated a high survival rate.^{6-12,25} The tilted implant employing the anatomical features of the arch has the advantage of expanding the prosthetic base of the arch.

Also of interest with regard to this treatment protocol is the need to reduce the number of implants. There is evidence that two implants used to support three-unit fixed partial dentures are an effective solution for a limited edentulous span.^{26–28} Completely edentulous patients need to have six to eight implants placed.

With regard to the reduced number of dental units to be replaced, it seems that a missing second molar does not interfere with the patient's functional and aesthetic needs.^{11,21}

The advantages of strategic implant placement to avoid a sinus augmentation procedure should be weighed against the need for cross-sectional images incurring radiation and the extra cost involved, as well as, in some situations, the use of image-guided surgery. Because only 60.7% of cases could be completely restored, the choice of the most effective surgical plan remains controversial, but the more teeth that need replacement, the more advantages strategic implant planning can offer. In fact, two-thirds of sinus augmentation procedures can be avoided in cases of at least three missing teeth (Table 2). It should also be added that the use of radiographic guides, templates, and computerized planning software is recommended for complex cases.^{29,30} For one missing tooth, it seems that the sinus augmentation procedure with immediate implant placement when possible is the most appropriate solution because CT exams are not required. Although further investigations are necessary, particularly to determine the implant survival rate, the aesthetic outcome, and the use of a minimal amount of bone that can be expanded, the advantages of this surgical method as a therapeutic option are clear: it reduces surgical and treatment duration by eliminating the graft healing period, it reduces patient and practitioner discomfort and risk of morbidity resulting from the need for bone harvesting if autogenous bone is used, it reduces the cost, and it should increase patient acceptance, particularly for severely resorbed posterior maxillae if the bone has to be harvested in the iliac crest under general anesthesia.

CONCLUSION

This radiological study demonstrates that the use of a panoramic radiological exam for oral implant planning in severely resorbed maxillae overestimates the need for a sinus augmentation procedure when compared with the use of both three-dimensional planning software

and strategic implant placement when there is little remaining bone volume. This clinical procedure reduces the duration of surgery and treatment by eliminating the graft healing period, thus reducing the cost of treatment, patient and practitioner discomfort, and risks of morbidity. It should also increase patient acceptance, particularly if donor bone would otherwise have to be harvested from the iliac crest under general anesthesia.

REFERENCES

1. Boyne P, James RA. Grafting of the maxillary sinus floor with autogenous marrow and bone. *Int J Oral Maxillofac Surg* 1980; 38:113–116.
2. Wood M, Moore DL. Grafting of the maxillary sinus with intraorally harvested autogenous bone prior to implant placement. *Int J Oral Maxillofac Implants* 1988; 3:209–214.
3. Grazziani F, Donos N, Needleman I, Gabriele M, Tonetti M. Comparison of implant survival following sinus floor augmentation procedures with implants placed in pristine posterior maxillary bone: a systematic review. *Clin Implant Dent Relat Res* 2002; 4:69–77.
4. Chiapasco M, Zaniboni M, Rimondini L. Dental implants placed in grafted maxillary sinuses: a retrospective analysis of clinical outcome according to initial clinical situation and a proposal of defect classification. *Clin Oral Implants Res* 2008; 19:416–428.
5. Del Fabro M, Rosano G, Taschieri S. Implant survival rates after maxillary sinus augmentation. *Eur J Oral Sci* 2008; 116:497–506.
6. Krekmanov L. Placement of posterior mandibular and maxillary implants in patients with severe bone deficiency: a clinical report of procedure. *Int J Oral Maxillofac Implants* 2000; 15:722–730.
7. Aparicio C, Perales P, Rangert B. Tilted implants as an alternative to maxillary sinus grafting: a clinical, radiologic, and periosteal study. *Clin Implant Dent Relat Res* 2001; 3:39–49.
8. Fortin Y, Sullivan RM, Rangert BR. The Marius implant bridge: surgical and prosthetic rehabilitation for the completely edentulous upper jaw with moderate to severe resorption: a 5-year retrospective clinical study. *Clin Implant Dent Relat Res* 2002; 4:69–77.
9. Calandriello R, Tomatis M. Simplified treatment of the atrophic posterior maxilla via immediate/early function and tilted implants: a prospective 1-year clinical study. *Clin Implant Dent Relat Res* 2005; 7(Suppl 1):S1–S12.
10. Koutouzis T, Wennström JL. Bone level changes at axial- and non-axial-positioned implants supporting fixed partial dentures. A 5-year retrospective longitudinal study. *Clin Oral Implants Res* 2007; 18:585–590.
11. Balleri P, Ferrari M, Veltri M. One-year of implants strategically placed in the retrocanine bone triangle. *Clin Implant Dent Relat Res* 2010; 12:324–330.

12. Fortin T, Isidori M, Bouchet H. Placement of posterior maxillary implants in partially edentulous patients with severe bone deficiency using CAD/CAM guidance to avoid sinus grafting: a clinical report of procedure. *Int J Oral Maxillofac Implants* 2009; 24:96–102.
13. Fugazzotto PA. Shorter implants in clinical practice: rationale and treatment results. *Int J Oral Maxillofac Implants* 2008; 23:487–496.
14. Romeo E, Ghisolfi M, Rozza R, Chiapasco M, Lops D. Short (8-mm) dental implants in the rehabilitation of partial and complete edentulism: a 3- to 14-year longitudinal study. *Int J Prosthodont* 2006; 19:586–592.
15. Harris D, Buser D, Dula K, et al. Guidelines for the use of diagnostic imaging in implant dentistry. *Clin Implant Dent Relat Res* 2002; 13:566–570.
16. Jacobs R, Adriansens A, Naert I, Quirynen M, Hermans R, van Steenberghe D. Predictability of reformatted computed tomography for pre-operative planning of endosseous implants. *Dentomaxillofac Radiol* 1999; 28:37–41.
17. Jacobs R, Adriansens A, Verstreken K, Suetens P, van Steenberghe D. Predictability of a three-dimensional planning system for oral implant surgery. *Dentomaxillofac Radiol* 1999; 28:105–111.
18. Van Assche N, van Steenberghe D, Guerrero ME, et al. Accuracy of implant placement based on pre-surgical planning of three-dimensional cone-beam images: a pilot study. *J Clin Periodontol* 2007; 34:816–821.
19. McKee IW, Glover KE, Williamson PC, Lam EW, Heo G, Major PW. The effect of vertical and horizontal head positioning in panoramic radiography on mesiodistal tooth angulations. *Angle Orthod* 2001; 71:442–451.
20. Rangert B, Jemt T, Jörn us L. Forces and moments on Br nemark implants. *Int J Oral Maxillofac Implants* 1989; 4:241–247.
21. Kayser AF. Shortened dental arch: a therapeutic concept in reduced dentitions and certain high-risk groups. *Int J Periodontics Restorative Dent* 1989; 9:426–444.
22. Ulm CW, Solar P, Krennmair G, Matejka M, Watzek G. Incidence and suggested management of septa in sinus-lift procedures. *Int J Oral Maxillofac Implants* 1995; 10:462–465.
23. Friberg B. The posterior maxilla: clinical considerations and current concepts using Br nemark system implants. *Periodontol* 2000 2008; 47:67–78.
24. Renouard F, Nisand D. Short implants in the severely resorbed maxilla: a 2-year retrospective clinical study. *Clin Implant Dent Relat Res* 2005; 7:S104–S110.
25. Malo P, Rangert B, Nobre M. All-on-4 immediate-function concept with Br nemark System implants for completely edentulous maxillae: a 1-year retrospective clinical study. *Clin Implant Dent Relat Res* 2005; 7:S88–S94.
26. Buser D, von Arx T. Surgical procedures in partially edentulous patients with ITI implants. *Clin Oral Implants Res* 2000; 11:S83–S100.
27.  strand P, Engquist B, Dahlgren S, Grondahl K, Engquist E, Feldmann H. Astra Tech and Br nemark system implants: a 5-year prospective study of marginal bone reactions. *Clin Oral Implants Res* 2004; 15:413–420.
28. Eliasson A, Eriksson T, Johansson A, Wennerberg A. Fixed partial prostheses supported by 2 or 3 implants: a retrospective study up to 18 years. *Int J Oral Maxillofac Implants* 2006; 21:567–574.
29. 2010 guidelines of the Academy of Osseointegration for the provision of dental implants and associated patient care. *Int J Oral Maxillofac Implants* 2010; 25:620–627.
30. Fortin T, Coudert JL, Champeboux G, Sautot P, Lavallee S. Computer assisted dental implant surgery using computed tomography. *J Image Guid Surg* 1995; 1:53–58.